

A Modified Theroux Phase I Retainer Design

KEVIN L. THEROUX, DDS, MS

Hawley retainers, single-thickness thermoformed retainers, and bonded lingual retainers are all commonly used for Phase I retention. Each appliance has its advantages and drawbacks.

Although the Hawley retainer is rigid enough to maintain palatal expansion and is easily trimmed and durable, its mechanical retention can be problematic in patients with short clinical crowns or exfoliated deciduous teeth, and the labial bow crossing the occlusion in the canine areas can interfere with tooth eruption. Fabrication requires substantial laboratory time, wire-bending skills, and a second appointment to seat the appliance, adding to its cost.

A 1mm, single-layer thermoformed appliance is relatively inexpensive and can be quickly fabricated and seated at the end of the appliance-removal appointment. This kind of retainer is easily broken, however, and may not be rigid enough to maintain palatal expansion or to allow trimming for newly erupted teeth.

Bonded retainers hold the incisor positions well and are not cooperation-dependent, but require significant chairtime to place or remove. Additionally, they do not retain palatal expansion, are frequently broken, and are difficult to use in patients with deep overbites.

In 2003, I introduced a thermoformed Phase I retainer designed to overcome the drawbacks of

the other retention alternatives.¹ This article describes an updated and simplified version.

Retainer Design

The original Theroux Phase I Retainer consisted of a single layer of 1mm Essix type ACE* material over the permanent incisors and first molars and a double thickness of the same material covering the palate (Fig. 1). The double palatal thickness added rigidity and allowed the retainer to be easily trimmed for erupting teeth. This appliance provided excellent retention, with no clasps and no labial wire to interfere with canine eruption.

A disadvantage of the original design was that the single-thickness material over the molars, which was intended to prevent vertical occlusal changes, often fractured. The retainer can usually be worn without the molar extensions, but even in

*Dentsply Raintree Essix, Inc., Sarasota, FL; www.essix.com.

**Trademark of Great Lakes Orthodontics, Tonawanda, NY; www.greatlakesortho.com.

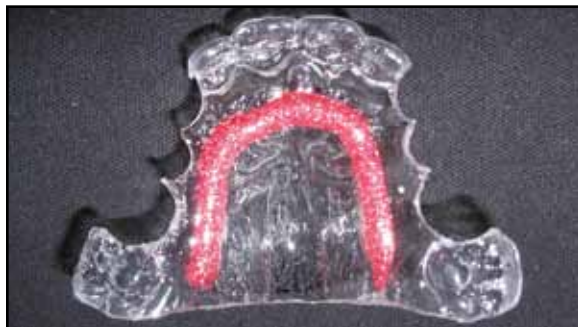

Fig. 1 Original Theroux Phase I Retainer, made from Essix type ACE* material.



Fig. 2 Updated Theroux Phase I Retainers made from Patterned Biocryl.**



Dr. Theroux is in the private practice of orthodontics at 10450 Park Meadows Drive, Lone Tree, CO 80124; e-mail: info@drtheroux.com.

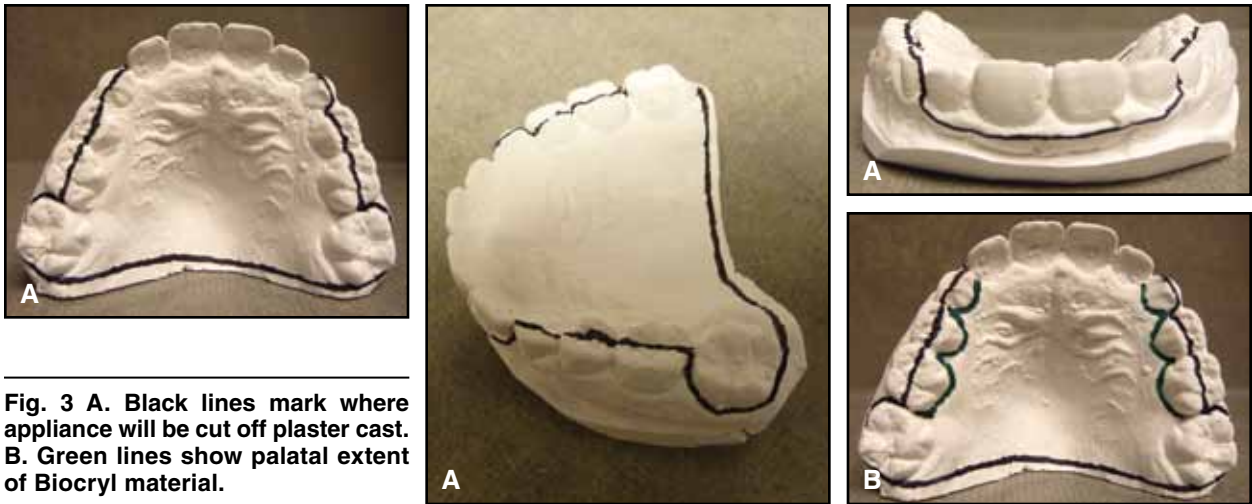


Fig. 3 A. Black lines mark where appliance will be cut off plaster cast. B. Green lines show palatal extent of Biocryl material.

these cases, I could see no vertical effects, probably because the appliance is worn only while sleeping.

To address the breakage problems of the original design, I began making the entire appliance out of 2mm thermoformed material in 2005 (Fig. 2). The double thickness over the molars does not appear to cause any vertical changes in the patient's occlusion. This version retains all the advantages of the original design over alternative retainers and can be made in colorful patterns that appeal to young patients.

Fabrication

1. Take an alginate impression of the maxillary arch and pour it in quick-set plaster.
2. Rough-trim the cast to allow seating in the thermoforming machine.
3. With a black felt-tipped marker, draw a line across the model's palatal surface, connecting the distopalatal surfaces of the first permanent molars. Continue the line along the buccogingival borders of the first molars, across the occlusal surfaces of the deciduous molars and canines, and along the labiogingival borders of the incisors (Fig. 3A).
4. Use a green felt-tipped marker to draw a line

along the lingual surfaces of the deciduous teeth, just occlusal to the gingival margins (Fig. 3B). This line marks the palatal border of the appliance.

5. Thermoform 2mm clear Splint Biocryl** or Patterned Biocryl** over the cast, using a positive-pressure machine.

6. Cut completely through the plastic material with an Essix wheel saw,* following the black lines on the cast (Fig. 4A). Pry the appliance from the cast using a wax spatula or lab knife.

7. Holding the appliance, trim the material back to the green lines along the gingival margins of the deciduous molars with an acrylic bur (Fig. 4B). In most cases, the green lines will transfer to the Biocryl material after thermoforming, but they may occasionally need to be retraced onto the Biocryl. Use the acrylic bur to finish the rough edges left by the wheel saw. No polishing is necessary; the retainer is now ready to be delivered (Fig. 4C).

Total fabrication time for the appliance is about 15 minutes once the plaster cast has been trimmed. Because clear Splint Biocryl material is easier to trim than Patterned Biocryl and the black and green reference lines are more easily seen, I recommend making the first few appliances out of the clear material. Patterned Biocryl appliances

A Modified Theroux Phase I Retainer Design

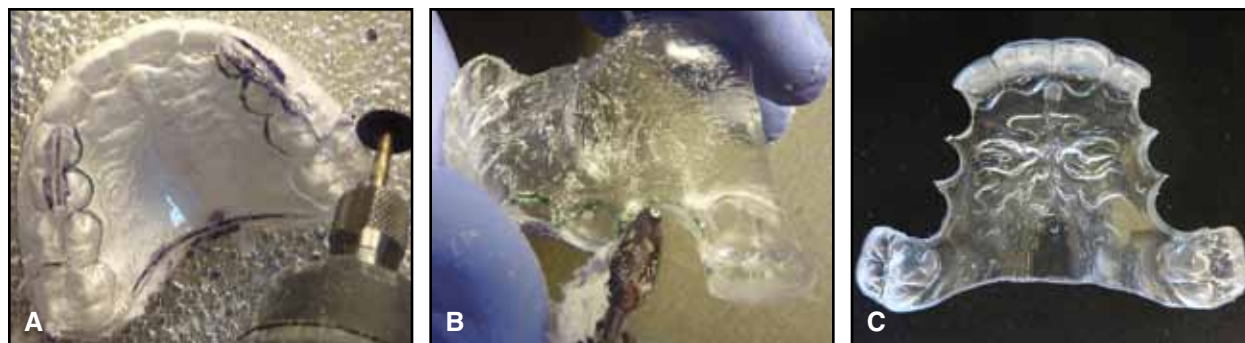


Fig. 4 A. Wheel saw used to cut material off cast. B. Acrylic bur used to trim appliance. C. Final appliance made from clear Splint Biocryl.

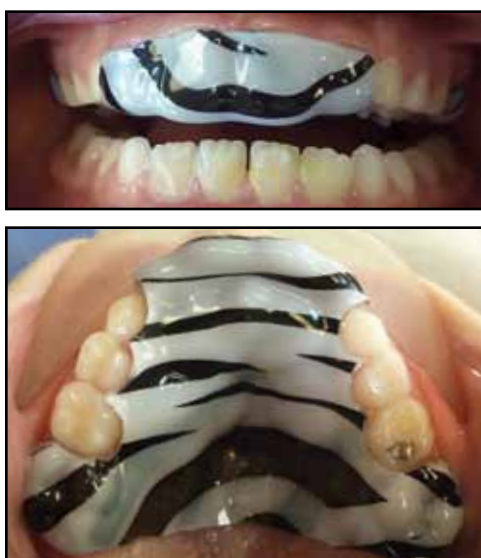

Fig. 5 Final appliance made from Patterned Biocryl.

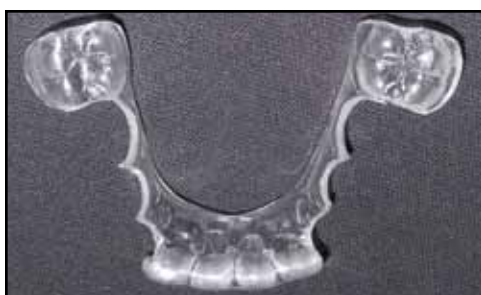

Fig. 6 Mandibular version of updated Theroux Phase I Retainer.

(Fig. 5) are slightly more durable and may therefore be preferred once the technician is familiar with the procedure and no longer needs the reference lines. Patients also seem to like the Patterned Biocryl retainers.

8. Show the patient how to seat the appliance by pushing on the palate and incisors and how to remove it by pulling down in the incisor region. Instruct the patient to wear the retainer only while sleeping and to call the office immediately if it no longer seats due to ectopic eruption of permanent teeth. The appliance is easily adjusted with an acrylic bur in a slow-speed handpiece. Six-month retainer checks are typical.

A similar appliance can be fabricated for the mandibular arch (Fig. 6). When taking the impression, it is important to record the tissue gingival to the lingual aspects of the deciduous teeth. This allows the lingual extensions of the appliance to be long enough occlusogingivally to prevent fracture.

Conclusion

The modified Theroux Phase I Retainer can be fabricated entirely in the office without wire bending. Only a single layer of material is thermoformed, avoiding the 30-minute curing time for dual Essix layers. This inexpensive, durable, and retentive appliance maintains palatal expansion and incisor positions with only nighttime wear, does not interfere with normal canine and premolar eruption, and can be adjusted as needed for atypical dental eruption. It also works well to preserve leeway space. Since fabrication takes only about 15 minutes, the retainer can be delivered at the appliance-removal appointment. Young patients find it easy to place and remove the retainer and appreciate the choice of patterns. In addition, much less staff time is required than with a Hawley retainer.

REFERENCES

1. Theroux, K.L.: A new vacuum-formed Phase I retainer, *J. Clin. Orthod.* 37:384-387, 2003.